Pre-expanded Anterolateral Thigh Perforator Flap for Phalloplasty

Salvatore D'Arpa, MD, PhD*, Britt Colebunders, MD, Filip Stillaert, MD, Stan Monstrey, MD, PhD

KEYWORDS

• Phalloplasty • Skin expansion • ALT flap • LCFA flap • Perforator flap • Pre-expanded flap

KEY POINTS

- The anterolateral thigh (ALT) perforator flap is a valuable alternative to the radial forearm flap for patients who do not wish to have the forearm scar.
- ALT flap phalloplasty leaves visible scarring in the thighs owing to skin grafting of its donor site.
- Pre-expansion of an ALT flap allows primary donor site closure.
- Preoperative perforator location with computed tomography angiography is crucial to the success of the procedure.

INTRODUCTION

Since the first description in 2005,[1] phalloplasty with a free or pedicled anterolateral thigh (ALT) flap has gradually gained popularity for penile reconstruction[2–14] as an alternative to the standard radial forearm flap (RFF).[15]

The main advantage of the ALT flap in this indication is avoidance of the large forearm scar, which has become a recognizable sign of this operation because of the increasing attention received from the media. Very large flaps are needed for a phalloplasty and the donor site subsequently needs skin grafting. As a result, the donor site is quite noticeable because a hairless skin graft with a depression is left at the donor site. If the donor site is located in the forearm, it is not only quite visible and difficult to conceal unless long sleeves are worn, but also a recognizable sign of the operation performed (**Fig. 1**).

If an ALT flap is used for phalloplasty, the RFF donor site scars are avoided. However, a donor site scar will be present in the thigh, combined with the scars needed for skin graft harvest (**Fig. 2**). With the RFF and ALT, there is not only the flap donor site scar, but also the split thickness skin graft donor site, which is often more painful than the flap donor site itself.

There is a particular subset of patients who want to avoid both scars because, although the thigh scars can be easily concealed whit a pair of shorts while dressed, they cannot be concealed when naked and are very close to the genital area. These patients would rather avoid disfigurement of the area that is the center of their masculinity and intimacy. Pre-expansion of the ALT allows donor site scarring to be minimized in these patients (**Fig. 3**).

TREATMENT GOALS AND PLANNED OUTCOMES

Pre-expansion of a conventional ALT flap has 3 main goals:

1. Allowing primary donor site closure;
2. Improving the perforator's vascular territory;
3. Thinning of the flap.

Disclosure Statement: The authors have nothing to disclose.
Department of Plastic and Reconstructive Surgery, Ghent University Hospital, De Pintelaan, 185, K12C, Gent 9000, Belgium
* Corresponding author.
E-mail address: salvatore.darpa@uzgent.be

Clin Plastic Surg 44 (2017) 129–141
http://dx.doi.org/10.1016/j.cps.2016.08.004

Fig. 1. Postoperative result of a radial forearm flap (RFF) phalloplasty showing the typical scar at the donor site. Because this is the only application for use of such a large RFF, this scar has become a recognizable sign of the operation, which not all patients like to have. Scars in the thigh are also present due to harvest of STSGs for coverage of the RFF donor site.

In this particular application, the goal of preoperative expansion of the ALT flap is achieving primary donor site closure. Improving the perforator's vascular territory is not needed in this case. The flap measures 14 × 18 cm on average and survival is not an issue. Partial flap necrosis is a very uncommon occurrence, even without prior expansion. Selection of the largest perforator with the aid of a preoperative computed tomography (CT) angiography warrants complete flap survival.

Flap thinning would be extremely desirable and was one of the goals we planned of pursuing when we first started expanding the ALT. Unfortunately, for this particular flap 2 expanders need to be placed medially and laterally to the perforator and expansion only results in a peripheral thinning of the flap with the flap's fat being squeezed toward the perforator in the middle of the flap. This kind of deformation is of little use in a phalloplasty because a lot of bulk is created in the middle of the flap, where it cannot be thinned out.

The planned outcome of preoperative ALT expansion in phalloplasty is to allow primary donor site closure, avoid the disfiguring scar and the painful skin graft donor site in the thigh.

Fig. 2. Postoperative result of an anterolateral thigh (ALT) and superficial circumflex iliac perforator flaps phalloplasty. Although concealable with regular clothing, when naked the scars in the thigh, owing to both ALT and split thickness skin graft harvest, are apparent.

PREOPERATIVE PLANNING AND PREPARATION

Preoperative location of the perforator is crucial to flap planning. A CT angiography is used for this purpose.[10] The CT angiography allows the most distal perforator with the largest caliber, the longest (to comfortably reach the pubis), with the best subcutaneous branching and the most convenient intramuscular or septal course, providing a preoperative navigation that cannot be obtained by simple Doppler location.

The radiologist provides distances from the anterior superior iliac spine based on an *x–y* axis (**Fig. 4**) drawn on the thigh and the position of the perforator is marked on the patient's skin. The flap is drawn accordingly with the perforator lying along its midline and close to its proximal margin. Then the expander's base (20 × 7 cm) is drawn outside of the flap's borders (**Fig. 5**) because, as described, placing the expanders in the flap will squeeze the fat toward the midline, which is not desirable in this case.

PATIENT POSITIONING

The patient is placed in the supine position. The ipsilateral arm can be abducted or adducted

Fig. 3. Expanded anterolateral thigh and superficial circumflex iliac perforator flaps phalloplasty donor site, 5 months postoperatively. For comparison, here is an early postoperative image of a phalloplasty after expansion. The donor site has been closed with an inverted "Y" scar and no skin graft donor site is present in the thigh. The scars are still red but already much less disfiguring than those in Fig. 2.

based on the surgeon's preference. Abduction will provide greater room for the placement of the lateral expander because the hand, with the arm adducted, comes in close proximity to the lateral incision and pocket.

PROCEDURAL APPROACH

Expander Placement

Two remote "W" incisions[16] are performed some centimeters caudal to the inguinal ligament (see Fig. 5) and deepened to the deep fascia. Then the 2 pockets are dissected, bluntly or with the cautery, with the aid of a lighted retractor to obtain hemostasis. Care must be taken not to deepen the plane too much because the sensory nerves lie on top of the fascia and they must not be damaged. Once the pocket is complete, a superficial (3–5 mm of fat left on the skin flap) pocket is dissected cranially to the incision to allow for remote port placement in a position that shall be as easily accessible as possible (Fig. 6). Before expander placement, two 12-F suction drains are placed in the pocket. The air is emptied from the expanders and they are partially filled with methylene blue–tinted saline, which allows easy visualization of the fluid coming out of the expanders during ambulatory postoperative expansion. Partial inflation keeps the expander distended and allows easy placement without folding (Fig. 7). Once the expander and ports are in position, easy accessibility of the ports is double checked before closure (Figs. 8 and 9).

Donor Site Closure

At the time of flap transfer (Fig. 10), the flap is harvested first, with the expander left in place to maintain skin stretch and inflated with extra 100 to 150 mL to obtain some intraoperative expansion.

Donor site closure begins with expander and valve removal through the easy access of the defect left by the flap. Dissection is suprafascial and then on the plane of the deep capsule of the expander, which will result in division of the capsule into a superficial and a deep part. While the deep part is not touched, the superficial is scored extensively to maximize the advancement of the skin flaps, extending the capsular incision to the superficial fascia in a way very similar to galeal scoring in the scalp (Fig. 11). Then the flaps are brought together and temporarily held together with skin staples. Two big dog ears will form distally that are eventually resected, resulting in inverted "Y" or "T" scars (Figs. 12–16). Suction drains are placed underneath the flaps.

POTENTIAL COMPLICATIONS AND THEIR MANAGEMENT

There are no specific complications of ALT flap pre-expansion; potential complications are those commonly related to tissue expansion. Like any specific body region, the anatomy accounts for some peculiarities. In the thigh, the subcutaneous fat is quite dense, fibrous, and thick, and skin perforation and exposure is very unlikely.

We have observed 2 leaks from the inflation ports that needed replacement likely owing to puncture with an exceedingly large needle. Infection can be a complication and can be prevented with appropriate technique. We have had an infection when we associated liposuction to expander placement. Infection is treated with expander removal, culture-guided antibiotic therapy and expander re-placement once the infection is cured. Placement without the aid of an CT angiography carries the risk of discontinuation of the procedure because the right perforator is missed.

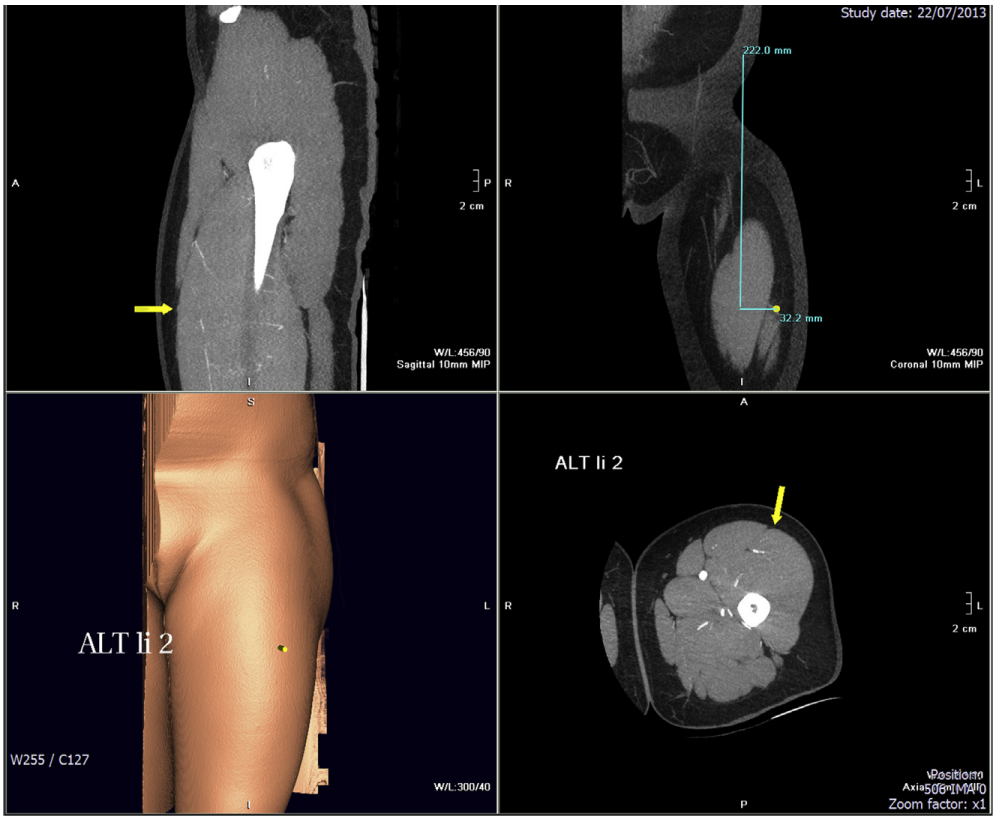

Fig. 4. An example of a preoperative computed tomography angiography. The sagittal (*upper left*), coronal (*upper right*), and axial (*lower right*) views of the perforator course together with a 3-dimensional reconstruction of the skin with the projection on the skin of the point of emergency from the fascia of the perforator (*lower left*), are provided. In the upper right coronal view, the distances measured from the anterior superior iliac spine are provided. Thus in a single image information about the course and position of the perforator are provided.

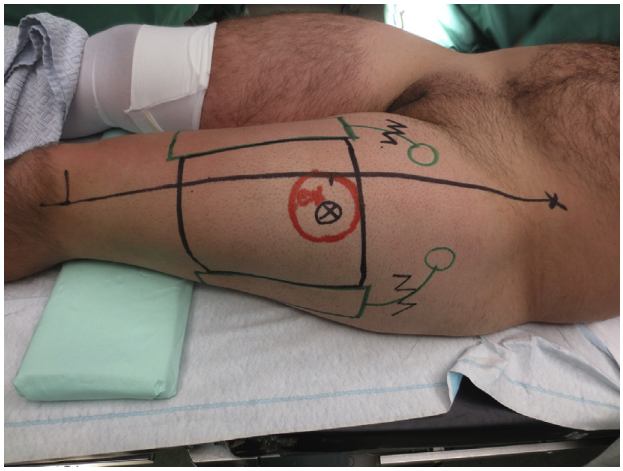

Fig. 5. Same patient as **Fig. 4**. A line is drawn connecting the anterior superior iliac spine (ASIS) to the upper lateral border of the patella. Using the angiographic computed tomography measurement in **Fig. 4**, the projection on the skin of the perforator is marked with a black, circled X, exactly 222 mm below and 32 mm laterally from the ASIS. Afterward the flap is drawn (*black rectangle*). The skin projection of the 2 expander pockets is drawn just lateral and medial to the flap to have little overlapping with the flap once the expanders are inflated. The expander base and remote ports are drawn in green. The ports are placed in an easily reachable position when the patient is lying supine. The "W" incisions (*black*) are placed in between.

POSTPROCEDURAL CARE

Patients are immediately mobilized and discharged after drain removal. Expansions are begun after 2 weeks and are usually performed

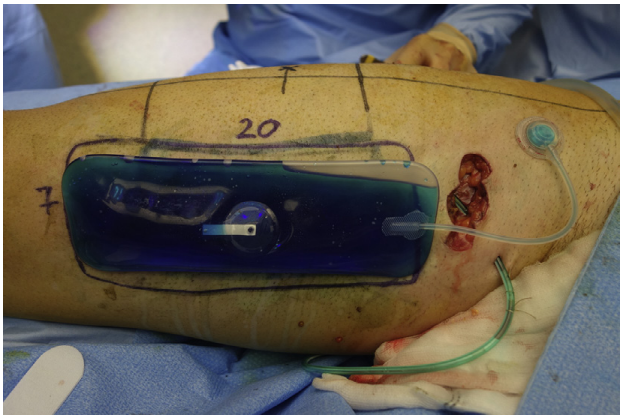

Fig. 6. Medial view of a right thigh (the knee is on the left hand side of the picture) at the time of expander placement. The pocket has already been dissected through the "W" incision, which allows wider exposure with the same length compared with a linear incision. The drain is in place. Saline (150 mL) colored with methylene blue is injected in the expander after all air has been removed. The expander is placed on the skin in the same position that it will eventually have inside the pocket.

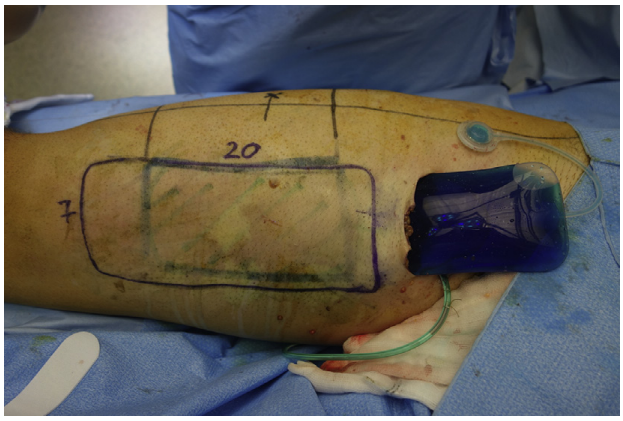

Fig. 7. Same view as in **Fig. 6**. The partial inflation of the expander facilitates insertion by keeping it distended and avoiding folding.

weekly. The whole process usually takes 4 to 6 months. It is thus initiated approximately 6 months before phalloplasty.

Overexpansion is usually performed and is stopped until a circumference gain of at least 14 cm has been obtained. During this period, especially when the expanders are fully inflated, physical activity is limited because the volume of the expanders restricts movement. Sports and activities that involve lower limb movements and that are at risk for trauma to the thighs are restricted. The patients comply well and wear larger trousers to accommodate the inflated expanders.

REHABILITATION AND RECOVERY

Once the expanders are removed and the flap transferred, recovery is relatively fast and no specific rehabilitation is needed. Because of the phalloplasty, the patients stay in bed for 10 days. When allowed to walk, no specific problems have been observed.

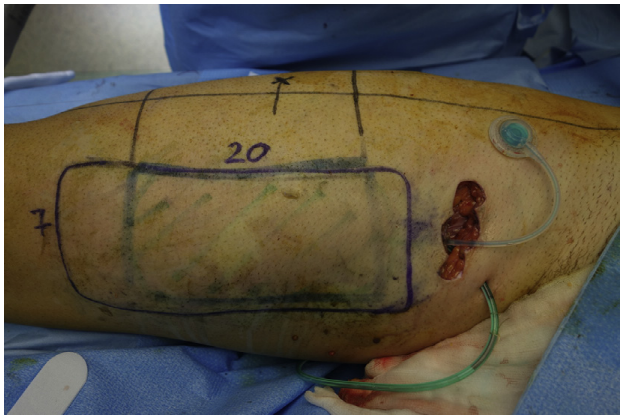

Fig. 8. Same view as in **Figs. 6** and **7**. The remote port is inserted last. The pocket for the port is dissected in a different – more superficial – plane and with a bottleneck to prevent the port from slipping back toward the incision once inserted.

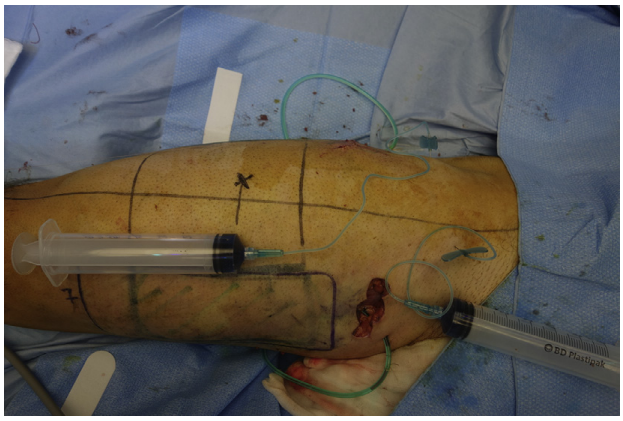

Fig. 9. Bird's eye view, knee on the left hand side. The figure shows the 2 expanders with the procedure completed for the lateral one and to be completed for the medial one, to show the 2 moments of placement of the needle in the port. The syringe on the right is connected to the medial port before closure. At this point, the port is probed to verify easy access before closure, for eventual replacement. The syringe on the right has been used for a final inflation of the expander after closure, to ensure obliteration of dead space within the pocket to avoid fluid collection.

OUTCOMES

The charts of 91 pedicled ALT flap phalloplasties performed between 2004 and 2016 were retrospectively reviewed. Nine patients (10%) underwent pre-expansion of the ALT flap in preparation for a pedicled ALT flap phalloplasties. Seven patients

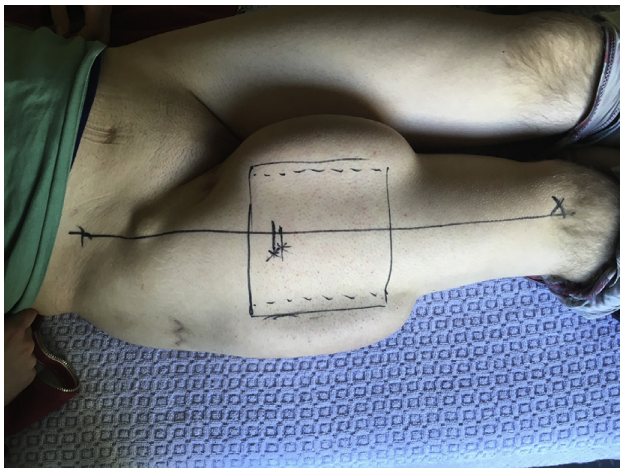

Fig. 10. Bird's eye view, knees on the right hand side. Preoperative markings of a right pre-expanded anterolateral thigh flap. The CT scan showed 2 septal perforators coming close to each other in this case. This picture shows how the expanders, although placed laterally to the flap, eventually – with inflation – do expand underneath the flap as well, causing some peripheral thinning.

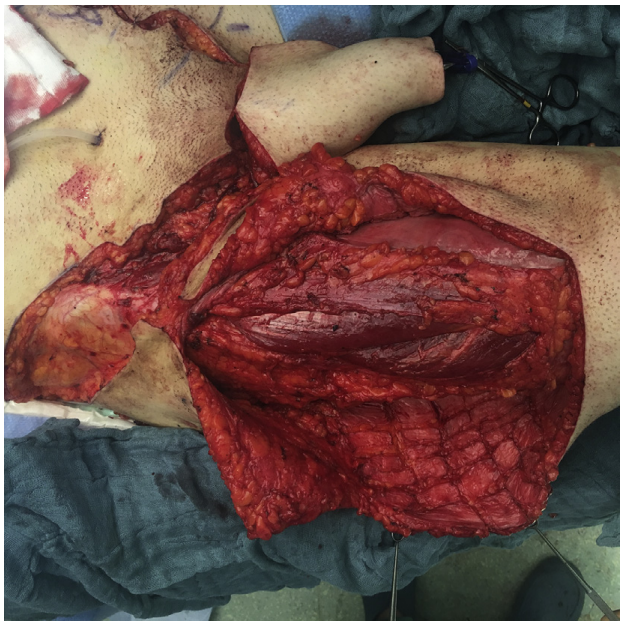

Fig. 11. Intraoperative, bird's eye view after flaps transfer. Knees on the right hand side. The anterolateral thigh flap is wrapped around the ipsilateral superficial circumflex iliac perforator flap (not visible) that has been used for urethral reconstruction and whose donor site is clearly visible. The thigh flaps for closure has been dissected and the capsular scoring is clearly visible on the lateral flap, held in the bottom of the picture by 2 skin hooks.

were operated for female-to-male sex reassignment surgery, 1 for reconstruction after penile amputation, and 1 for reconstruction after bladder extrophy (**Table 1**). Six patients had a preoperative CT scan.

Fig. 12. Same view as in **Fig. 11**. The wound edges have been temporarily approximated with skin staples and 2 dog ears form distally.

Fig. 13. Close up view of the distal dog ears. The midpoint is brought proximally with forceps to show the correction needed to eliminate the 2 dog ears.

Seven of 9 patients underwent eventual phalloplasty with an ALT flap (see **Table 1**). In 1 patient (case 2 in **Table 1**) who had no preoperative CT angiography, no suitable perforator was identified and the procedure was converted in a free RFF phalloplasty. Another patient (case 8 in **Table 1**) had an infection that eventually forced removal of the implants. Because of this delay and of a significant weight gain that caused fat thickening in the

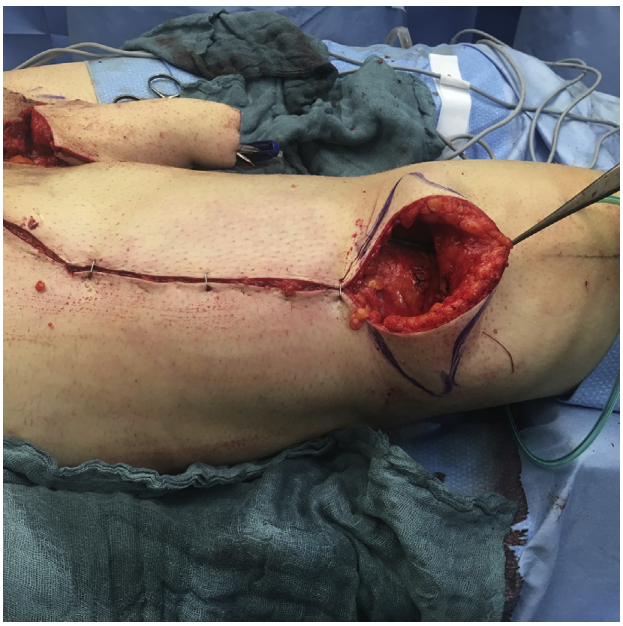

Fig. 14. Lateral view of the wound on the right thigh (*knee on the right hand side*). The skin resection is drawn in blue. Fat resection will extend further to avoid residual dog ears. The forceps are kept in the same position as **Fig. 13** to allow for comparison.

Fig. 15. Donor site after closure. The resulting scar is an inverted "Y".

thigh, we abandoned the ALT flap phalloplasty and performed an RFF phalloplasty instead.

In cases 2 and 3, there was a leak from the expander inflation ports that required their replacement. The expanders did not deflate. The leak was probably due to the use of a large needle for inflation.

Fig. 16. Four years postoperative result. Despite some scar widening in the middle, the scar is little visible. No skin graft harvest scars are present. The inverted "T" can be seen distally above the knee.

The only infection was observed in the patient in whom we performed flap liposuction for thinning purposes in the same operation as expander placement (case 8 in **Table 1**). Because it is only 1 case, we cannot conclude that liposuction might be related to infection. More data are needed, although it seems that performing the 2 procedures simultaneously is better avoided if possible.

Donor site closure was primary with a double dog ear resection distally that resulted in an inverted "T" or "Y" appearance in 6 cases and with 2 opposed advancement flaps in 1 case. After flap harvest, all donor sites but one healed uneventfully. This case (case 6 in **Table 1**) had 2 advancement flaps for donor site closure, the medial of which had a partial necrosis with a wound dehiscence that eventually required skin grafting. We would discourage use of these 2 flaps for donor site closure and we would use 2 big rotation flaps—if flaps are needed because primary closure is not possible—instead.

There were no flap-related complications like partial or total necroses.

In 2 cases (cases 1 and 2 in **Table 1**) lipofilling was performed twice for correction of a contour deformity in the thigh.

CASE DEMONSTRATIONS

Case 1

A 36-year-old female to male transgender patient was admitted for phalloplasty with a pre-expanded ALT flap combined with a free RFF for urethral reconstruction (**Figs. 17–19**; see **Table 1**, Case 5). Two rectangular expanders of 750 mL each were implanted on the left thigh and expanded with 1000 mL until a 14-cm circumference gain was achieved, which took 11 weeks. Seven months after expander placement, phalloplasty was performed with the pre-expanded ALT flap combined with a free RFF. The RFF was anastomosed end to side to the femoral artery and end-to-end to the greater saphenous vein. The pedicled ALT flap was transferred as a pedicled flap with 2 sensory nerves that were anastomosed to 1 ilio-inguinal nerve and to one of the dorsal clitoral nerves. The ALT flap donor site was closed primarily. Coronaplasty was performed 6 weeks after the initial operation. Erectile and testicular implants were placed 3 years after the operation. One year later, a minor correction was performed to reduce the penile size. At 5 years follow-up the patient is doing fine.

Case 2

A 29-year-old female-to-male transgender patient (see **Table 1**, Case 9) was admitted for a

Table 1
Patients data

Patient	Diagnosis	First Procedure	Phalloplasty	Donor Site Closure	Complications	Date Operated (ALT Flap)	Secondary Procedures
1	FTM	Expander placement	Previous phallo + Pedicled ALT	Primary	None	10/2004	Lipofilling
2	FTM	Expander placement	Pedicled ALT	Primary	Expander leakage	08/2009	Lipofilling
3	BEX	Expander placement	RFF (no good ALT perforators	NA	Expander leakage	NA	None
4	SCC	Expander placement	Pedicled ALT + free RFF	Primary	None	06/2010	None
5	FTM	Expander placement	Pedicled ALT + free RFF	Primary	None	03/2011	None
6	FTM	Expander placement	Pedicled ALT + pedicled SCIAP	Advancement flaps	Donor wound dehiscence	11/2015	None
7	FTM	Expander placement	Pedicled ALT + pedicled SCIAP	Primary	None	12/2015	None
8	FTM	Expander placement + thinning by liposuction	Free RFF (refused ALT)	NA	Infection	NA	None
9	FTM	Expander placement	Pedicled ALT + pedicled SCIAP	Primary	None	04/2016	None

Abbreviations: ALT, anterolateral thigh; BEX, bladder extrophy; FTM, female to male; NA, not applicable; RFF, radial forearm flap; SCC, squamous cell carcinoma; SCIAP, superficial circumflex iliac perforator flap.

Fig. 17. Case 1 (see text for details). Three-quarters preoperative view of the expanded thigh.

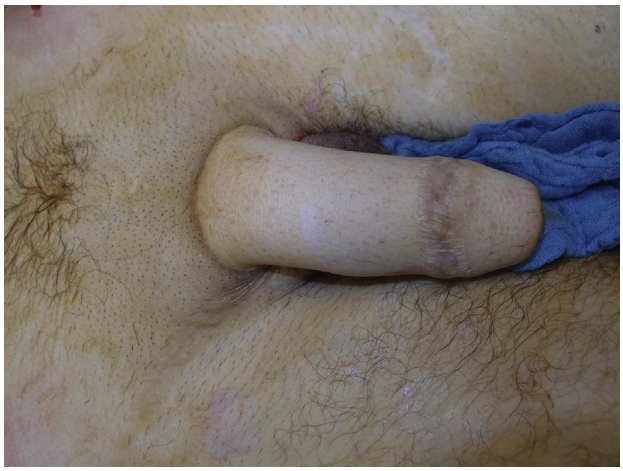

Fig. 19. Case 1 (see text for details). Postoperative view after volume reduction of the phallus by narrowing the base with a wedge resection on the ventral side.

phalloplasty with a pre-expanded ALT flap and a superficial circumflex iliac perforator flap for urethral reconstruction because he wanted no scars in his forearm (**Figs. 20–23**). Two 750-mL rectangular expanders were placed in his right thigh and inflated, over 13 weeks, with 1000 and 775 mL. Four months after the operation, the patient underwent a phalloplasty with a pedicled ALT flap combined with a pedicled superficial circumflex iliac perforator flap for urethral reconstruction. Two lateral femoral cutaneous nerve branches harvested with the ALT flap were connected to 1 ilio-inguinal nerve and 1 dorsal clitoral nerve. The procedure was uncomplicated and the donor sites were closed primarily. Coronaplasty has not yet been performed. The patient had a postoperative urinary infection that was treated with antibiotics and, 1 year after the operation, is voiding well and waiting for coronaplasty and placement of erectile and testicular implants.

Case 3

A 43-year-old patient (see **Table 1**, case 4) came to our attention for penile reconstruction after amputation for a squamous cell carcinoma (**Figs. 24–28**). Two 750-mL rectangular tissue expanders were placed in the right thigh based on perforator location with a CT angiography. Because the superficial circumflex iliac perforator flap was unavailable due to scarring from the previous groin sentinel node biopsy, a pre-expanded RFF was planned as well and another 750-mL expander placed in the left forearm. The RFF was anastomosed end to side to the femoral artery and end-to-end to the greater saphenous vein and the pedicled ALT flap wrapped around it with its cutaneous sensory nerves connected to 1 ilio-inguinal nerve and to one of the dorsal nerves of the glans. Coronaplasty was performed 1 week later. One year after the operation, an erectile implant was placed.

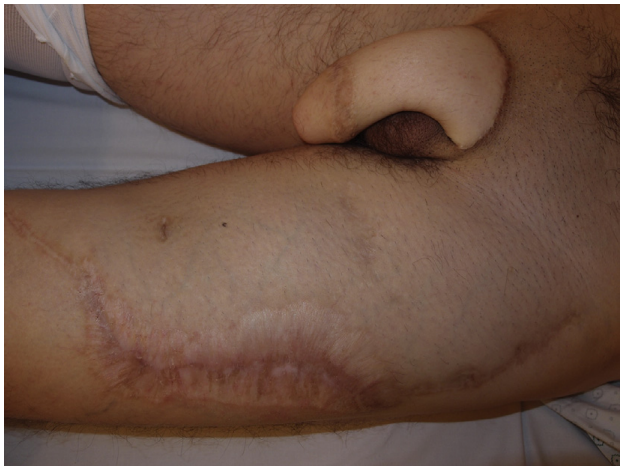

Fig. 18. Case 1 (see text for details). Postoperative view before penile correction. The linear thigh scar has widened, probably owing to some residual tension.

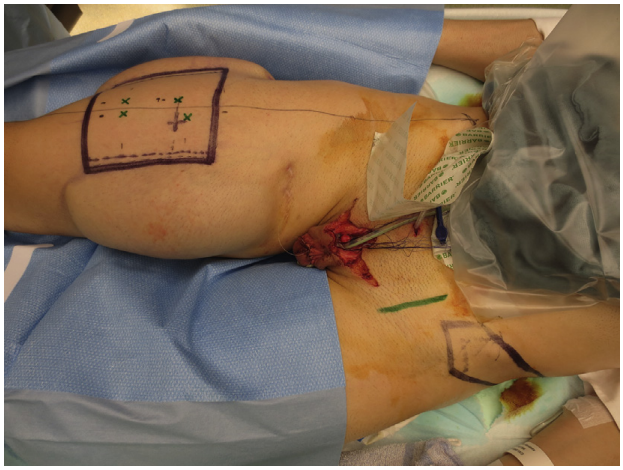

Fig. 20. Case 2 (see text for details). Intraoperative view after completion of vaginectomy and reconstruction of the fixed part of the urethra, before phalloplasty.

Fig. 21. Case 2 (see text for details). Postoperative frontal view showing 2 dog ears that will fade over time and the contour deformity of the right thigh.

Fig. 22. Case 2 (see text for details). The left lateral view shows the linear scar of the superficial circumflex iliac perforator flap that extends far laterally to obtain an adequate pedicle length to reach the pubis.

DISCUSSION

The first case report of a pre-expanded free ALT came from Tsai,[17] who visualized the perforators through a large incision and placed a subfascial expander. Other reports followed[18–21] of its use as a free flap in burn wounds with the dual advantages of thinning the flap and closing the donor site primarily or reducing the skin graft and potentially increasing vascularity. As described above, the increase in vascularity is not needed and the usefulness of thinning the flap cannot be applied to phalloplasty. When the flap is thinned by expansion, the flap above the expander thins out but the part where the pedicle enters the flap stays thicker.

There are also some reports of pre-expanded flaps in phalloplasty surgery with the RFF,[22] the suprapubic flap,[23] or scapular flap.[24] In these cases, just a reduction of the area to be grafted and an insensate phallus are obtained, whereas a pre-expanded ALT flap always allows preservation of flap's innervation.

Over the years, we have refined our technique to optimize outcomes. A CT angiography is used routinely to accurately locate perforators and expanders are placed accordingly. This way the unfortunate occurrence observed in patient 3 of **Table 1** is avoided (**Fig. 29**). Expansion is routinely carried out until a circumference gain corresponding to the flap's width is achieved. Closure is performed directly and a dog ear usually forms distally, which is excised resulting in an inverted "T" or "Y" design. Patient are instructed on wearing large trousers to accommodate the bulk of the expanders. The flap can be farther thinned to the level of the suprascarpal fat provided that the regions were the nerves and the perforator lie are avoided. This thinning might sometimes result in a temporary venous congestion (fast capillary refill) that normally subsides within 30 minutes. The ALT flap is harvested without any fascia and is best tunneled underneath the rectus femoris and sartorius muscles, and then through a wide subcutaneous tunnel, to reach the pubic area. If an appropriate perforator is chosen based on CT angiography studies, the perforator is long enough to transfer a pedicled flap and avoid microsurgical anastomoses. The patient is kept with his thigh slightly bent to avoid any traction on the pedicle

Fig. 23. Case 2 (see text for details). Close up view of the external urinary meatus, made of the suture of the superficial circumflex iliac perforator and the anterolateral thigh flaps.

for the first 3 days. Once the flap is tubed, any tension must be avoided. If there is any tension that might cause flap compression with postoperative edema, a skin graft is best placed ventrally to relieve this tension and avoid vascular compromise.

The presence of the expanders is cause of discomfort, especially toward expander completion, because the expanders hold a considerable volume. Patients try to partially conceal the expanders by wearing very large trousers. It is indeed a procedure for a small group of patients (10%) in our series, who accept the presence of the expanders and the additional operation and ambulatory inflations needed to reduce the donor site scarring. These patients must be very well-informed and have sufficient motivation because they have to put extra effort to go

Fig. 25. Case 3 (see text for details). Left lateral intraoperative view. The belly is on the right hand side. The free radial forearm flap is wrapped around the drain placed into the bladder through the urethra and the anterolateral thigh (ALT) flap is ready to be wrapped around it. The nerves ready for coaptation can be seen coming from the ALT flap.

Fig. 24. Case 3 (see text for details). Preoperative view after completion of tissue expansion in the forearm and thigh.

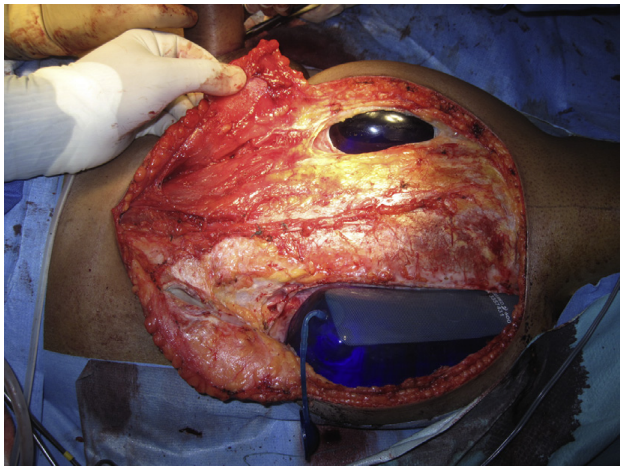

Fig. 26. Case 3 (see text for details). Intraoperative view before expander removal. The fascia has been closed.

Fig. 27. Case 3 (see text for details). Three-quarters right postoperative view shows some widening and discoloration of the scar, not uncommon in people with dark skin.

Fig. 28. Case 3 (see text for details). Widening and discoloration are observed also in the forearm skin.

SUMMARY

Preoperative expansion is a valuable tool for minimizing donor site scarring in ALT flap phalloplasty because it allows not only prevention of the unsightly donor site graft, but also scarring and pain related to a split thickness skin graft harvest. Preoperative perforator location with a CT angiography allows minimally invasive expander placement.

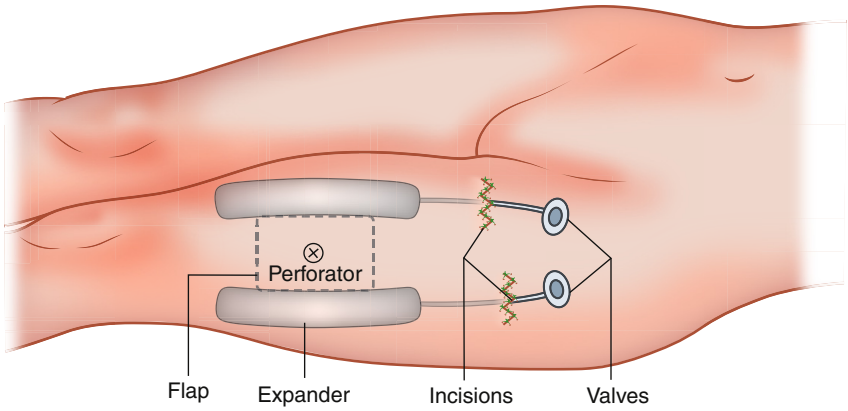

Fig. 29. This schematic drawing shows how incisions, expander, and valves shall be placed once the perforator is located by means of a CT scan. For more information, see **Figs. 4** and **5** and the relative legends, and the "preoperative planning and preparation" and "procedural approach: expander placement" sections.

through a longer process, additional operations, and extra costs.

Also, it has to be pointed out that in this cases reduction of scars is achieved at the expenses of contour. It has to be discussed with the patient that indeed the patch like scars due to skin grafting will be avoided. But avoidance of scars comes at the expenses of contour because the thinned expanded skin will cause a depression and a contour deformity in the thigh that will need future lipofilling sessions to be corrected.

REFERENCES

1. Ceulemans P. The Pedicled Anterolateral Thigh Flap (ALT) Perforator Flap: A New Technique for Phallic Reconstruction. Paper presented at the XIV Biennial Symposium of the Harry Benjamin International Gender Dysphoria Association (HBIGDA). Bologna, Italy, April 6–9, 2005.
2. Felici N, Felici A. A new phalloplasty technique: the free anterolateral thigh flap phalloplasty. J Plast Reconstr Aesthet Surg 2006;59:153–7.

3. Mutaf M, Isik D, Bulut Ö, et al. A true nonmicrosurgical technique for total phallic reconstruction. Ann Plast Surg 2006;57:100–6.
4. Lumen N, Monstrey S, Selvaggi G, et al. Phalloplasty: a valuable treatment for males with penile insufficiency. Urology 2008;71(2):272–6.
5. Lumen N, Monstrey S, Ceulemans P, et al. Reconstructive surgery for severe penile inadequacy: phalloplasty with a free radial forearm flap or a pedicled anterolateral thigh flap. Adv Urol 2008;704343.
6. Descamps MJ, Hayes PM, Hudson DA. Phalloplasty in complete aphallia: pedicled anterolateral thigh flap. J Plast Reconstr Aesthet Surg 2009;62(3):e51–4.
7. Lee GK, Lim AF, Bird ET. A novel single-flap technique for total penile reconstruction: the pedicled anterolateral thigh flap. Plast Reconstr Surg 2009; 124(1):163–6.
8. Rubino C, Figus A, Dessy LA, et al. Innervated island pedicled anterolateral thigh flap for neo-phallic reconstruction in female-to-male transsexuals. J Plast Reconstr Aesthet Surg 2009;62(3):e45–9.
9. Rashid M, Aslam A, Malik S, et al. Clinical applications of the pedicled anterolateral thigh flap in penile reconstruction. J Plast Reconstr Aesthet Surg 2011; 64(8):1075–81.
10. Sinove Y, Kyriopoulos E, Ceulemans P, et al. Preoperative planning of a pedicled anterolateral thigh (ALT) flap for penile reconstruction with the multidetector CT scan. Handchir Mikrochir Plast Chir 2013; 45(4):217–22.
11. Liu CY, Wei ZR, Jiang H, et al. Preconstruction of the pars pendulans urethrae for phalloplasty with digestive mucosa using a prefabricated anterolateral thigh flap in a one-arm patient. Plast Reconstr Surg Glob Open 2013;1(7):e53.
12. Holzbach T, Giunta RE, Machens HG, et al. Phalloplasty with pedicled anterolateral thigh flap ("ALT-Flap"). Handchir Mikrochir Plast Chir 2011;43(4): 227–31 [in German].
13. Hasegawa K, Namba Y, Kimata Y. Phalloplasty with an innervated island pedicled anterolateral thigh flap in a female-to-male transsexual. Acta Med Okayama 2013;67(5):325–31 [Erratum appears in Acta Med Okayama 2014;68(3):183].
14. Morrison SD, Son J, Song J, et al. Modification of the tube-in-tube pedicled anterolateral thigh flap for total phalloplasty: the mushroom flap. Ann Plast Surg 2014;72(Suppl 1):S22–6.
15. Monstrey S, Hoebeke P, Selvaggi G, et al. Penile reconstruction: is the radial forearm flap really the standard technique? Plast Reconstr Surg 2009; 124:510–8.
16. Matton GE, Tonnard PL, Monstrey SJ, et al. A universal incision for tissue expander insertion. Br J Plast Surg 1995;48(3):172–6.
17. Tsai FC. A new method: perforator-based tissue expansion for a preexpanded free cutaneous perforator flap. Burns 2003;29:845–8.
18. Hallock GG. The preexpanded anterolateral thigh free flap. Ann Plast Surg 2004;53:170–3.
19. Hallock GG. Tissue expansion techniques to minimize morbidity of the anterolateral thigh perforator flap donor site. J Reconstr Microsurg 2013;29(9):565–70.
20. Acartürk TO. Aesthetic reconstruction of the postburn neck contracture with a preexpanded anterolateral thigh free flap. J Craniofac Surg 2014;25(1):e23–6.
21. Hocaoğlu E, Arıncı A, Berköz Ö, et al. Free pre-expanded lateral circumflex femoral artery perforator flap for extensive resurfacing and reconstruction of the hand. J Plast Reconstr Aesthet Surg 2013;66(12):1788–91.
22. Solinc M, Kosutic D, Stritar A, et al. Preexpanded radial forearm free flap for one-stage total penile reconstruction in female-to-male transsexuals. J Reconstr Microsurg 2009;25(6):395–8.
23. Terrier JÉ, Courtois F, Ruffion A, et al. Surgical outcomes and patients' satisfaction with suprapubic phalloplasty. J Sex Med 2014;11(1):288–98.
24. Dong L, Dong Y, He L, et al. Penile reconstruction by preexpanded free scapular flap in severely burned patient. Ann Plast Surg 2014;73(Suppl 1):S27–30.